Journal of Plastic, Reconstructive & Aesthetic Surgery (2007) **60**, 1352—1355

JPRAS
An International Journal of Surgical Reconstruction
www.JPRASurg.com

CASE REPORT

The innervated free toe web flap for clitoris reconstruction

Jörg Dabernig [a,b,*], Odhran P. Shelley [a], Jürgen Schaff [b]

[a] *Canniesburn Plastic Surgery Unit, Glasgow Royal Infirmary, Jubilee Building, 84 Castle Street, Glasgow G4 0SF, UK*
[b] *Plastic Surgery Center-Munich, Goethetrasse 4, 80335 Munich, Germany*

Received 17 July 2006; accepted 30 January 2007

KEYWORDS
Clitoris reconstruction;
Free flap;
Innervated toe web flap

Summary Clitoris reconstruction is often used in transgender reassignment. Most techniques now reconstruct the clitoris using glans pedicled on the dorsal phallic neurovascular bundle. Other techniques of clitoris reconstruction re-shape retained elements of the proximal segment of the corpora cavernosa, as well as techniques mobilising local flaps. We are presenting a new technique for clitoris reconstruction using an innervated free web space flap. The operative technique and outcome are illustrated and discussed in this case report.

Throughout history the clitoris has been known as the nympha, the virga and the amoris dulcedo (sweetness of love). According to O'Connell,[1] Estienne, in 1545 was the first to identify the clitoris in a work based on dissection, although he attributed it with a urinary function. Kaplan[2] relates that many clinicians believed that retained clitoral sensitivity in adulthood was abnormal. And indeed the role of the clitoris in female sexual function must still compete with Grafenberg's notion of an erotogenic zone within the vagina.[3] Nonetheless the clitoris has structures analogous to the male phallus, and a recognised role in female sexual function.[1—8]

Techniques to reconstruct the clitoris in transgender reassignment usually incorporate retained phallic remnants. Brown first used a method described by Hinderer for clitoris reconstruction in cases of intersex, whereby the dorsal portions of the glans penis were pedicled on the corpus spongiosum.[6] These were associated with failure from necrosis, if an adequate dorsal neurovascular pedicle was not included.[6—10] Most techniques now reconstruct the clitoris using glans pedicled on the dorsal phallic neurovascular bundle.[7—12] Other techniques of clitoris reconstruction re-shape retained elements of the proximal segment of the corpora cavernosa,[13] as well as techniques mobilising local flaps.[14]

The first web space flap was described by May et al. in 1977 and has a consistent innervation from the deep peroneal nerve, and can be raised either on the dorsalis pedis or plantar artery system.[15]

* Corresponding author. Canniesburn Plastic Surgery Unit, Glasgow Royal Infirmary, Jubilee Building, 84 Castle Street, Glasgow G4 0SF, UK. Tel.: +44 (0)141 211 5600; fax: +44 (0)141 211 5652.
E-mail address: joerg.dabernig@gmx.at (J. Dabernig).

1748-6815/$ - see front matter © 2007 Published by Elsevier Ltd on behalf of British Association of Plastic, Reconstructive and Aesthetic Surgeons.
doi:10.1016/j.bjps.2007.01.070

We present the case of a woman who had previous male to female transgender reassignment in whom the primary clitoral reconstruction failed. Secondary clitoris reconstruction was performed with a free toe web transfer.

Case report

A 35-year-old transgender patient had primary male to female gender reassignment surgery at another unit 18 months previously. At that time a pedicled glans reconstruction of the clitoris was performed. However, this reconstruction was unsuccessful, for reasons unknown. This reconstructed area then healed by secondary intention.

The patient presented seeking clitoris reconstruction, with complaint of insensitivity within the scarred site of failed reconstruction, and inability to achieve orgasm. Examination showed a small, scarred area at the site of the failed reconstruction. A proximal trigger point was suggestive of neuroma.

Because of scarring following previous surgery, relative absence of any significant phallic remnants, and the insensitivity of the area, reconstruction was planned using free tissue transfer of innervated vascularised tissue. A small volume of tissue was required, but one with well defined, yet expendable, sensory innervation. As such, reconstruction was planned using tissue from the first web space of the foot innervated by terminal branches of the deep peroneal nerve. During preoperative planning it was agreed with the patient that free tissue reconstruction would only be performed if suitable nerve remnants remained at the site of proposed reconstruction.

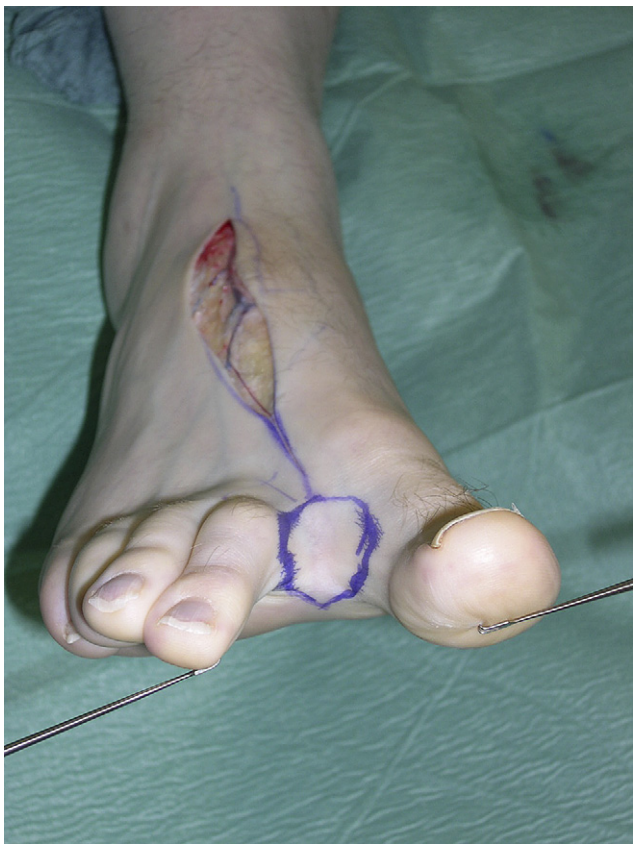

Figure 1 Flap harvest from first web space of the foot.

Figure 2 First web space flap prior to transfer. Flap demonstrating neurovascular bundle and two terminal branches of peroneal nerve.

The operation was carried out under spinal anaesthetic with sedation, by the senior author (J. Schaff). Surgical exploration of the previous reconstruction revealed small neuromata at the distal end of the dorsal phallic nerve remnants. Proximal to these neuromata the dorsal nerves were suitable for co-aptation. The neuromata were excised and the superficial epigastric vessels were prepared as recipient vessels.

A 2.0 × 1.5 cm free toe web flap (Fig. 1) was harvested from the first web space between the first and second toe of the right foot. It was raised on the dorsalis pedis artery system with the comitant veins. In addition two terminal branches of the deep peroneal nerve were identified and included in order to provide the sensory re-innervation necessary (Fig. 2). The donor site was covered with a full thickness skin graft.

Vascular anastomosis was performed between the dorsalis pedis artery and the inferior epigastric artery, and between a dorsal vein and the superficial epigastric vein.

Figure 3 Clitoris reconstruction following inset of toe web flap.

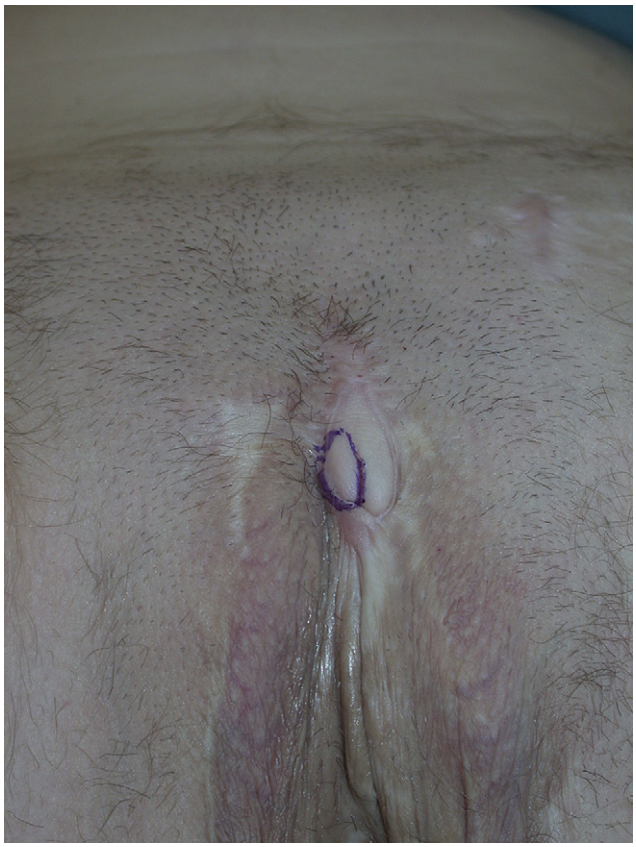

Figure 4 Area of clitoris reconstruction which regained vibration sensation 14 months post reconstruction.

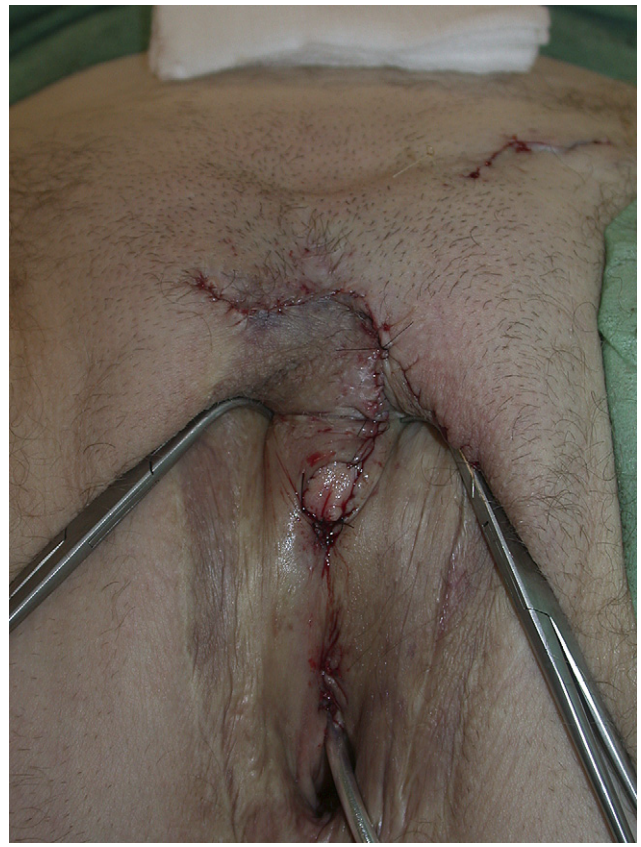

Figure 5 Reconstructed clitoris after further reconstruction of the clitoral prepuce. The prepuce was reconstructed using local flaps.

The peroneal nerve branches were co-apted with the two dorsal phallic nerves. The flap was created slightly larger than required, in order to facilitate inset and postoperative monitoring, and to provide sufficient volume in case of possible shrinkage (Fig. 3).

The patient had an uncomplicated postoperative recovery and both the reconstruction and donor site healed primarily. The patient was discharged from hospital five days after the operation.

The postoperative follow up 14 months following reconstruction showed evidence of satisfactory re-innervation with vibratory sensation. The patient stated that erogenous sensitivity had returned within an area illustrated (Fig. 4), which allowed the patient to achieve an orgasm lasting for 5—10 s, during penetration. A minor correction to improve the inset of the neo-clitoris was carried out under local anaesthetic with sedation 14 months postoperatively (Fig. 5). The donor site healed without complication.

Discussion

The clitoris is that part of the female external genitalia analogous to the penis in the male, and is capable of erogenous sensation.[16] As an anatomical part, its significance, function and its existence as an entity have been disputed over the millennia. Even the origins of the name of this body part are controversial. The Greek word κλειτοριζ (clitoris) is derived either from the word κλειτορ ιζειυ meaning to rub, or from a related word for hill. It is taken to mean 'little hill', and suggests that the name 'clitoris' is an ancient word play.[1]

Anatomically the clitoris has components which correspond both to the corpora and the glans of the penis, with both erectile and non-erectile components. Specific erotic sensation is mediated through mucocutaneous end organs[16] and large clitoral nerves are invariably present and analogous to the dorsal penile nerves.[1,4,5]

Anatomy of the glans clitoris in adult females shows it to be a densely neural structure with a large number of corpuscles of Pacini.[16] These are rapidly adapting receptors, which are incredibly sensitive and may be activated by as little as a puff of air on the skin.[17] They are found throughout the body, with increased density in glabrous skin, in particular adjacent to joints. According to Winkelmann, erogenous zones are found in mucocutaneous parts of the body with an inverse relationship between mucocutaneous sensory end organs and hair follicle density. A decreasing number is noted as one moves from glabrous to hair-bearing skin.[16,17]

In male to female gender reassignment, reconstruction may be performed using remnants of the corpora cavernosum, corpus spongiosum or glans penis, thereby providing tissue which is similar in function and innervation.[1,4,5] In the absence of these tissues locally we believe that the free toe pulp offers a suitable tissue match. In May's study of 50 fresh cadaver feet, he found the area to have

a consistent identifiable nerve supply.[15] As such, the first web space flaps have been used to increase sensibility in the injured hand.[15,18,19]

Innervated free tissue reconstruction of the male external genitalia has previously been described, both as isolated penile shaft reconstruction,[20] and shaft and glans reconstruction.[21] Sasaki et al. used glabrous skin of the toe pulp in addition to an osseocutaneous radial forearm flap, as an innervated total penile reconstruction. They chose toe pulp because of similarity in texture between the toe pulp and glans tissue and noted return of erogenous sensation in the neo-glans following reconstruction.[22]

As we become increasingly aware of physical, emotional and psychological distress associated with clitoris loss, ability to reconstruct it becomes important. Analogous to the penis, the clitoris has both erectile function and non-erectile components, is non hair bearing, and is richly innervated, providing erogenous sensation. Reconstruction therefore provides a challenge to reproduce these needs in a small innervated free flap. We believe that the first web space flap provides tissue with consistent innervation, within a small and well defined area which contains analogous cutaneous receptors. The septated parenchyma is tissue which is similar in texture to the glans clitoris, and is an area where a high density of erogenous mucocutaneous receptors is expected.[16] It is also tissue which is easily expendable and as such is an ideal flap for clitoris reconstruction. Co-aptation to nervi erigentes provides an opportunity for erogenous re-innervation.

We believe the first web space innervated free flap provides an excellent clitoris reconstruction, with erogenous sensitivity. We performed this reconstruction in a transgender reassignment patient, but this technique may be equally useful in those patients who have had ablation following tumour resection or genital mutilation.

References

1. O'Connell HE, Sanjeevan KV, Hutson JM. Anatomy of the clitoris. *J Urol* 2005;**174**:1189—95 [Review].
2. Kaplan HS. *The New Sex Therapy: Active Treatment of Sexual Dysfunctions*. London: Bailliere Tindall; 1974. p. 544.
3. Grafenberg E. The role of the urethra in female orgasm. *Int J Sexol* 1950;**3**:145—8.
4. O'Connell HE, Hutson JM, Anderson CR, et al. Anatomical relationship between urethra and clitoris. *J Urol* 1998;**159**:1892—7.
5. Baskin LS, Erol A, Li YW, et al. Anatomical studies of the human clitoris. *J Urol* 1999;**162**:1015—20.
6. Brown J. Creation of a functional clitoris and aesthetically pleasing introitus in sex conversion. In: Marchac D, Hueston JT, editors. *Transactions of the Sixth International Congress of Plastic and Reconstructive Surgery*. Paris: Masson; 1976. p. 654—5.
7. Rubin SO. Sex-reassignment surgery male-to-female. Review, own results and report of a new technique using the glans penis as a pseudo clitoris. *Scand J Urol Nephrol Suppl* 1993;**154**: 1—28.
8. Fang RH, Chen CF, Ma S. A new method for clitoroplasty in male-to-female sex reassignment surgery. *Plast Reconstr Surg* 1992;**89**:679—82.
9. Hage JJ, Karim RB. Sensate pedicled neoclitoroplasty for male transsexuals: Amsterdam experience in the first 60 patients. *Ann Plast Surg* 1996;**36**:621—4.
10. Krege S, Bex A, Lummen G, et al. Male-to-female transsexualism: a technique, results and long-term follow-up in 66 patients. *BJU Int* 2001;**88**:396—402.
11. Perovic SV, Stanojevic DS, Djordjevic ML. Vaginoplasty in male transsexuals using penile skin and a urethral flap. *BJU Int* 2000; **86**:843—50.
12. Rehman J, Melman A. Formation of neoclitoris from glans penis by reduction glansplasty with preservation of neurovascular bundle in male-to-female gender surgery: functional and cosmetic outcome. *J Urol* 1999;**161**:200—6.
13. Meyer R, Kesselring UK. One-stage reconstruction of the vagina with penile skin as an island flap in male transsexuals. *Plast Reconstr Surg* 1980;**66**:401—6.
14. Giraldo F, Esteva I, Bergero T, et al. Andalusia Gender Team. Corona glans clitoroplasty and urethropreputial vestibuloplasty in male-to-female transsexuals: the vulval aesthetic refinement by the Andalusia Gender Team. *Plast Reconstr Surg* 2004;**114**:1543—50.
15. May Jr JW, Chait LA, Cohen BE, et al. Free neurovascular flap from the first web of the foot in hand reconstruction. *J Hand Surg [Am]* 1977;**2**:387—93.
16. Winkelmann RK. The erogenous zones: their nerve supply and its significance. *Mayo Clin Proc* 1959;**34**:39—47.
17. Dykes R, McBain D. Cutaneous Receptors. In: Morris SL, Orris P, editors. *ILO Encyclopedia of Health and Safety*. 4th edn. New York, Geneva: International Labour Office; 1997 [Ref 857400179].
18. Morrison WA, O'Brien BM, MacLeod AM, et al. Neurovascular free flaps from the foot for innervation of the hand. *J Hand Surg [Am]* 1978;**3**:235—42.
19. Tanaka Y, Tajima S, Yamamoto Y, et al. Successful reconstruction of a high-pressure injection injury of the hand using a first web flap of the foot. *J Reconstr Microsurg* 1993;**9**:55—9.
20. Khouri RK, Young VL, Casoli VM. Long-term results of total penile reconstruction with a prefabricated lateral arm free flap. *J Urol* 1998;**160**:383—8.
21. Cheng KX, Hwang WY, Eid AE, et al. Analysis of 136 cases of reconstructed penis using various methods. *Plast Reconstr Surg* 1995;**95**:1070—80 [discussion 1081—4].
22. Sasaki K, Nozaki M, Morioka K, et al. Penile reconstruction: combined use of an innervated forearm osteocutaneous flap and big toe pulp. *Plast Reconstr Surg* 1999;**104**:1054—8.